

## Investigating Neurological Correlates of Chiari Type I Symptomatology: A Diffusion Tensor Imaging Study of Cognition and Pain

*Michelle Hughes, James Houston, Mei-Ching Lien, Ilana Bennett, Sarel Vorster, Mark Luciano, Francis Loth, Phillip A. Allen*

### Purpose

Recent research has found cognitive deficits in CMI patients relative to healthy controls. This project used diffusion tensor imaging (DTI) to assess white matter structural integrity in a case-control study, along with neuropsych testing and a pain scale, to test the following hypotheses:

1. CMI patients will display differences (relative to controls) for the diffusion parameters: FA, RD, MD.
2. Diffusion parameters will be associated with RBANS scores and chronic pain.
3. Cognitive deficits will persist in the CMI sample after controlling for chronic pain.

### Methods

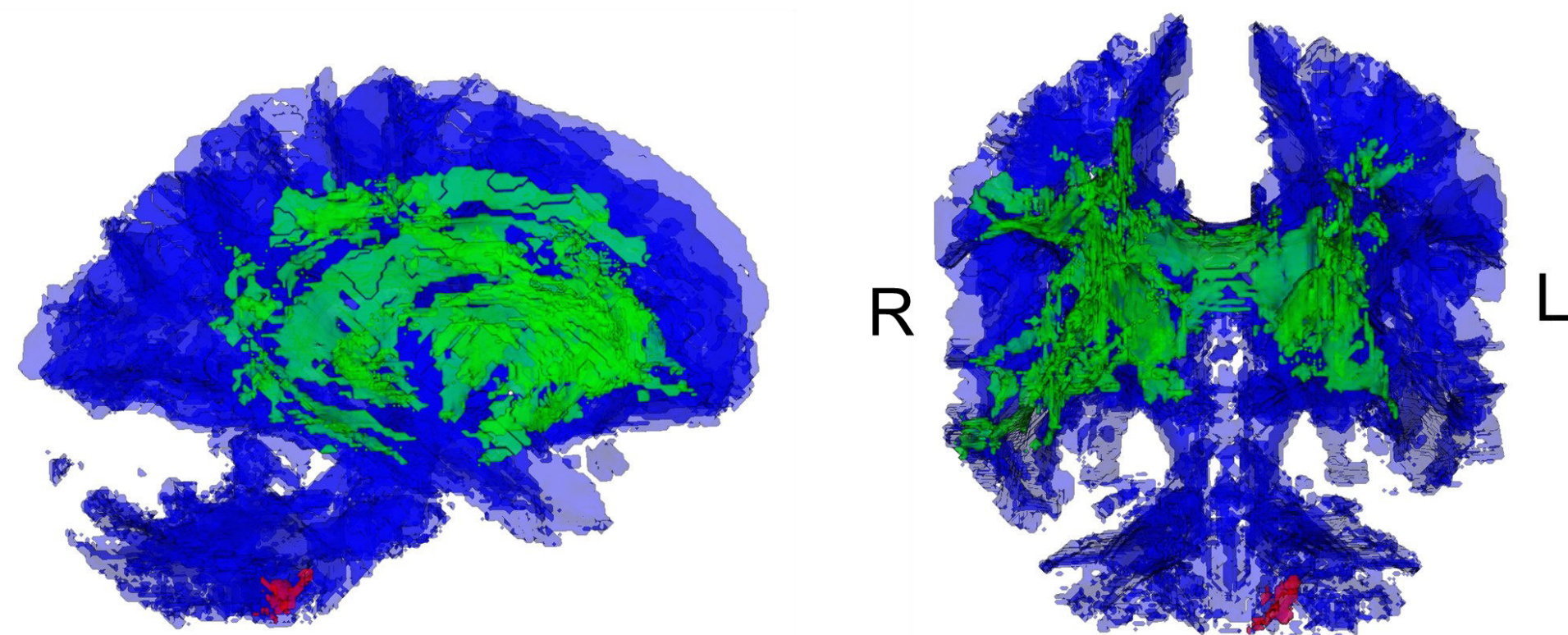
Eighteen adult Chiari patients and 18 matched controls underwent DTI imaging. Participants also completed the RBANS clinical assessment and a self-reported measure of pain.

### Results

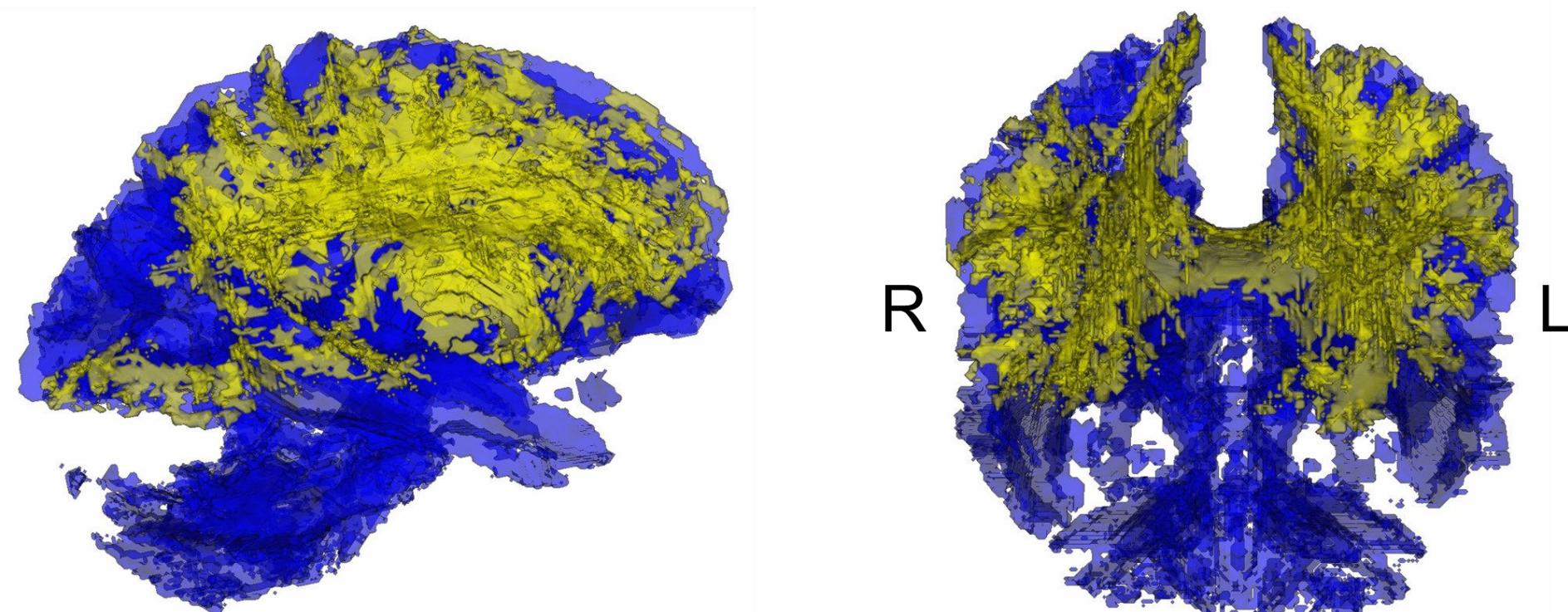
DTI found differences in CMI patients relative to age, education, and gender-matched controls. In the left cerebellar body, greater FA was associated with and greater self-report chronic pain and poorer attentional performance on a standardized clinical assessment. Furthermore, the correlation between cerebellar FA and attention persisted after statistically controlling for pain. On the other hand, FA in the cingulum was correlated with pain, but not with cognitive effects. Thus, the present result support a functional dissociation between cognitive performance and self-reported pain levels from standardized clinical assessments. In diffuse regions encompassing the cingulum, corpus callosum, and cerebrum, the DTI metrics of MD and RD were found to also be associated with chronic pain.

### Conclusions

The DTI differences found in this study add to the growing evidence that Chiari has a negative effect on cognitive function. Though the underlying mechanisms of the observed white matter effects remain elusive, they are likely to be associated with regeneration and reorganization processes involving neuron and glial support cell formations. More work is needed to reveal the clinical utility of DTI in improving CMI diagnosis and the understanding of CMI pathophysiology.



Clusters of significant difference for FA between CMI patients and healthy controls. The red area indicates the cluster in the posterior cerebellum (arbor vitae) and the green area indicates the group differences in a diffuse cluster (corpus callosum and cingulate).



A global cluster of significant difference for MD between CMI patients and healthy controls presented in yellow.