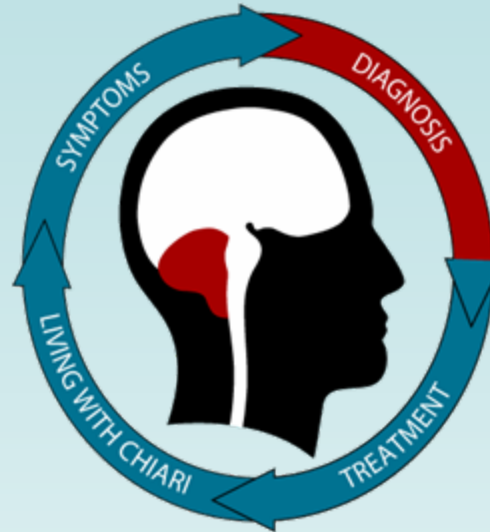




Chiari Malformation: **Diagnosis**



Rick Labuda, Executive Director

director@conquerchiari.org

724-940-0116

Graphics by Melissa S Neff

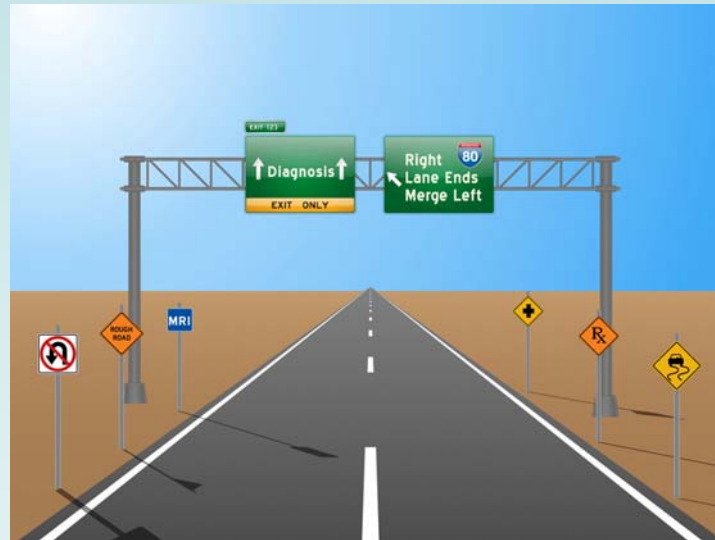Disclaimer: This presentation is intended for informational purposes only and may or may not apply to you. The editor and publisher are not doctors and are not engaged in providing medical advice. Always consult a qualified professional for medical care. This publication does not endorse any doctors, procedures, or products.

Road to Diagnosis



The paths people take to being diagnosed with Chiari are as numerous and varied as its many symptoms.

For some people, the path they follow is short and an accurate diagnosis comes quickly. They experience a sudden onset of symptoms often triggered by trauma. An MRI is ordered, and Chiari is discovered. The length of time from symptoms to discovery is measured in weeks or months.



For many people, the path is much longer. They experience a gradual onset of symptoms that worsen over time, see various specialists, and are often misdiagnosed with other conditions. The length of time from symptoms to discovery is measured in months or years.

Adult patients often go 5 years before being properly diagnosed.

Diagnostic Process

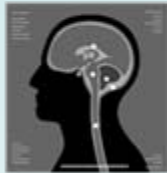

The diagnostic process involves several factors that a doctor, often a neurosurgeon, will take into account in making an informed decision.

Patient reported symptoms and whether they are likely caused by Chiari.



Evaluation of neurological signs and whether they are likely caused by Chiari



MRI evidence of abnormal anatomy: cerebellar tonsils out of position, narrow or blocked CSF spaces, crowding or compression of brain tissue, bony abnormalities, and/or presence of a syrinx



Physician's own **experience and judgment**



There is no single objective test to diagnose symptomatic Chiari.

Diagnostic Tests



Most common tests:

- **Neurological Exam**- a way to explore what is happening to the nervous system, by examining how different parts of the body respond to different forms of stimulus and functional tasks
- **MRI**- Magnetic Resonance Imaging, creates an image of the brain and spine
- **Cine-MRI**- also known as phase-contrast MRI, creates an image of the flow of spinal fluid



Other tests:

- X-Rays
- CT Scans
- Hearing
- Vision
- Upright MRI
- Vestibular
- Urodynamic
- Lumbar Puncture
- Neuropsychological

Experts recommend that anyone diagnosed with Chiari should have an MRI of their entire spine.

Neurological Exam



A complete neurological exam involves many tests, including:

Cranial Nerves

- 12 pairs of nerves in the brain responsible for sensation and function in the cranial area, such as: facial and eye movement, pupil dilation, smell, taste, swallowing, and sticking your tongue out.
- Tests to assess cranial nerve function might include whether strong odors can be detected, whether someone can smile or frown, and whether there are problems swallowing.

Coordination and Gait

- Coordination and gait tests can reveal problems in the nerves that provide feedback on muscle movement and position, balance, and cerebellar function.

Tests for coordination include:

Rapid alternating movements - touching your thumb to the tips of your fingers in succession

Point to point movements - touching something with your finger, then touching your nose

Romberg test - standing with your feet together and eyes closed for about 10 seconds

- Gait, or walking, requires many nerve functions to work together and is a good indication of problems in the nervous system.
- In addition to walking normally, a doctor may observe how a patient walks on their toes, walks on their heels, or walk heel-to-toe along a line.

Neurological Exam *cont.*



Reflexes

- Testing the deep tendon reflexes, the doctor uses a small hammer to strike a tendon and evaluates the response. In many CM/SM cases there will be an exaggerated response indicating a problem in a specific location.
- Reflexes are graded on a scale from 0-4, with 0 being no reflex and 4 being an abnormally strong reflex with clonus – a series of muscle contractions.

Reflex Grading Scale

Score	Description
0	No reflex
1+	Hypoactive (less than normal)
2+	Normal
3+	Hyperactive (more than normal)
4+	Hyperactive w/ clonus (like muscle spasm)

Motor Function

- Evaluation of motor function is essentially checking whether the nerves that supply your muscles are working.
- A doctor will evaluate muscle size, tone, and strength and look for weakness, imbalance between right and left sides and muscles that are too rigid or too soft.
- Muscle strength is rated on a scale from 0-5 and is measured by a patient's ability to resist force.

Motor Strength Assessment Scale

Score	Description
0	No muscle movement
1	Some visible movement
2	Full range of motion, not against gravity
3	Movement against gravity, but not resistance
4	Movement against resistance, less than normal
5	Normal Strength

Neurological Exam *cont.*



Spontaneous Venous Pulsations (SVPs)

- The veins in the retina in the back of the eye can be seen to pulsate when a doctor looks through the pupil.
- For people with elevated intracranial pressure – the pressure inside their head – these pulsations tend to not occur.
- If a doctor observes the lack of SVP's, it is a good indication of high intracranial pressure and might indicate a Chiari malformation (although some people naturally do not exhibit SVPs).

Sensation

- By testing with different stimulus at different locations, a doctor can locate potential problems.
- A sensation exam might include using a Q-tip to test for light touch, a tuning fork to test for vibration, and pin pricks. The exam will test sensation on the arms, legs, and other areas depending on the findings and patient history.
- Abnormal sensations in a given area, such as the shoulder, can be used to pinpoint both the type and location of a neurological problem.

Not every doctor will do a complete neurological exam, most will only do enough tests to decide if the neurological system is compromised.

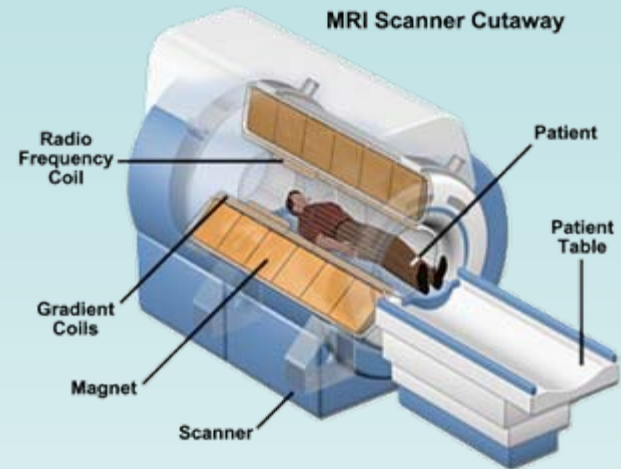
MRI

The magnetic resonance imaging process involves **Magnets**, **Resonance** (vibration), and **Imaging** (creating pictures).



What to expect:

- After the initial waiting time in the reception area, a technician will explain the process, ask a series of questions and lead you to the MRI room.
- Once inside the generally cold MRI room, you will lie down on a flat bed.
- Because the machine is loud, you will be given ear plugs to protect your ears, or headphones to listen to music and communicate with the technician.
- Depending on the equipment, a coil may be placed over your face like a mask.
- The bed will then slide into a tubelike insert, inside the machine, you will have a panic button to push in an emergency.
- For the next 20 minutes to an hour, the machine will make a series of loud noises, occasionally changing positions. ***It is critical to stay as still as possible for an accurate picture.***



During the first year, a patient can expect to undergo several MRI scans, with repeated follow ups in the years to come.

Phase-Contrast MRI



Phase-contrast (*cine-MRI*) – Phase-contrast is taken the same way as a traditional MRI, with the addition of either a wristband or EKG leads on the patient's chest to measure the heart rate.



The machine used is no different than the standard MRI test, however the operator will program the MRI a little differently and the computer that generates the image(s) will interpret the data it receives differently in order to show movement.

Allows for visualization of the flow of cerebrospinal fluid (*CSF*) and can be used to determine if a Chiari malformation is blocking the natural, back and forth flow of CSF between the brain and spine and by how much.

In Chiari cases with a syrinx, phase-contrast is a valuable tool in finding out if the syrinx is active.

Pediatric Diagnosis



- Children cannot always verbalize what they are feeling, sometimes the first clue is lack of proper development, either physically or cognitively
- Some children will bang their heads when they can't verbalize that their head hurts
- Symptoms may result in changes in behavior, attitude, and affect
- MRI requires the patient to remain still for an extended period of time which is not easy for a young child; young children may need to be anesthetized
- In older children, unusual presentations of scoliosis are a strong indication that an MRI should be performed



Pediatricians are becoming more aware of Chiari, resulting in quicker diagnoses for children.

Missed Diagnoses-Misdiagnoses



Missed Diagnoses occur when physicians ascribe initial symptoms to stress or other factors. Unfortunately, some patients are told their symptoms are psychological in nature. In other cases, patients are told that Chiari is not the cause of their symptoms or that Chiari is nothing to worry about and they were just born that way.

Misdiagnoses occur when the many possible symptoms of Chiari are associated to other conditions, such as: MS, Fibromyalgia, Chronic Fatigue, Lupus, Migraines, Carpal Tunnel Syndrome and ALS (Lou Gehrig's). These associations cause confusion to the medical situation and can result in critical delays in getting proper treatment.

Set of Symptoms	Conditions with similar symptoms
Headache Dizziness Weakness in arms/hands Numbness in arms/hands Leg Weakness Fatigue Tinnitus	Multiple Sclerosis Fibromyalgia Chronic Fatigue Lupus Migraines Carpal Tunnel ALS (Lou Gehrig's)

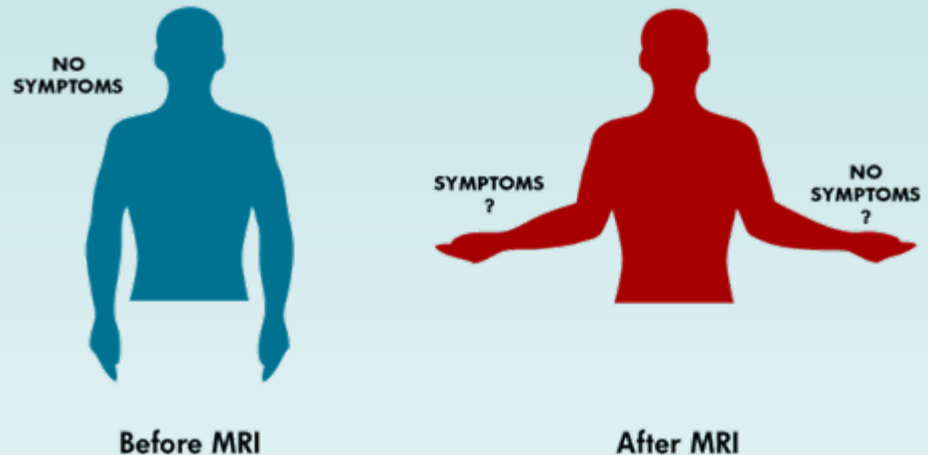
Milhorat's landmark study of over 300 Chiari patients found that over half of the patients had been told by a doctor that they suffered from a mental problem.

Incidental or Asymptomatic Diagnosis



The widespread use of MRIs has led to a new phenomenon, the incidental, or asymptomatic, Chiari diagnosis. An incidental diagnosis refers to a person who is found to have herniation of the cerebellar tonsils, but does not have symptoms usually associated with Chiari.

Although research indicates that many, possibly most, people with an incidental Chiari diagnosis are not likely to become symptomatic, it can be difficult for patients to not worry about the future. For children with an incidental diagnosis, parents must decide, based on little concrete information, whether any precautions should be taken.



Without a clear theory of how and why people become symptomatic, the incidental diagnosis remains a confusing problem for patients.

Reacting to the Diagnosis



Most people react one of two ways to diagnosis

For patients whose symptoms came on suddenly, the diagnosis can come as quite a shock

For patients who have struggled for years to find out what is wrong with them, a final diagnosis lends a sense of relief and vindication

Rapid worsening of symptoms

Awareness of disease makes some people more in tune with what is going on in their body

Symptoms that were in the background prior to a diagnosis are brought to the forefront

Connecting every symptom to Chiari

Second-order symptoms can develop, which aren't normally attributed to Chiari, but can be a result of life-style changes due to Chiari

The broad array of symptoms that Chiari can cause makes it difficult to say whether a given symptom is "due" to Chiari

Conquer Chiari – Learn More



Articles:

- [From The Desk of Regina S Bland, MD: Finding A Doctor...](#)
- [Magnetic Resonance Imaging](#)
- [The Neurological Exam](#)
- [How useful is measuring CSF Flow?](#)
- [Bridging The Patient-Doctor Communication Gap \(Part 1 of 3\)](#)
- [Bridging The Patient-Doctor Communication Gap \(Part 2 of 3\)](#)
- [Bridging The Patient-Doctor Communication Gap \(Part 3 of 3\)](#)
- [Talking About Chiari With Others....](#)

Books:

- [Conquer Chiari: A Patient's Guide](#)
- [Contents Under Pressure](#)

For a powerpoint copy of this presentation, or if you have any questions,
simply email: director@conquerchiari.org